

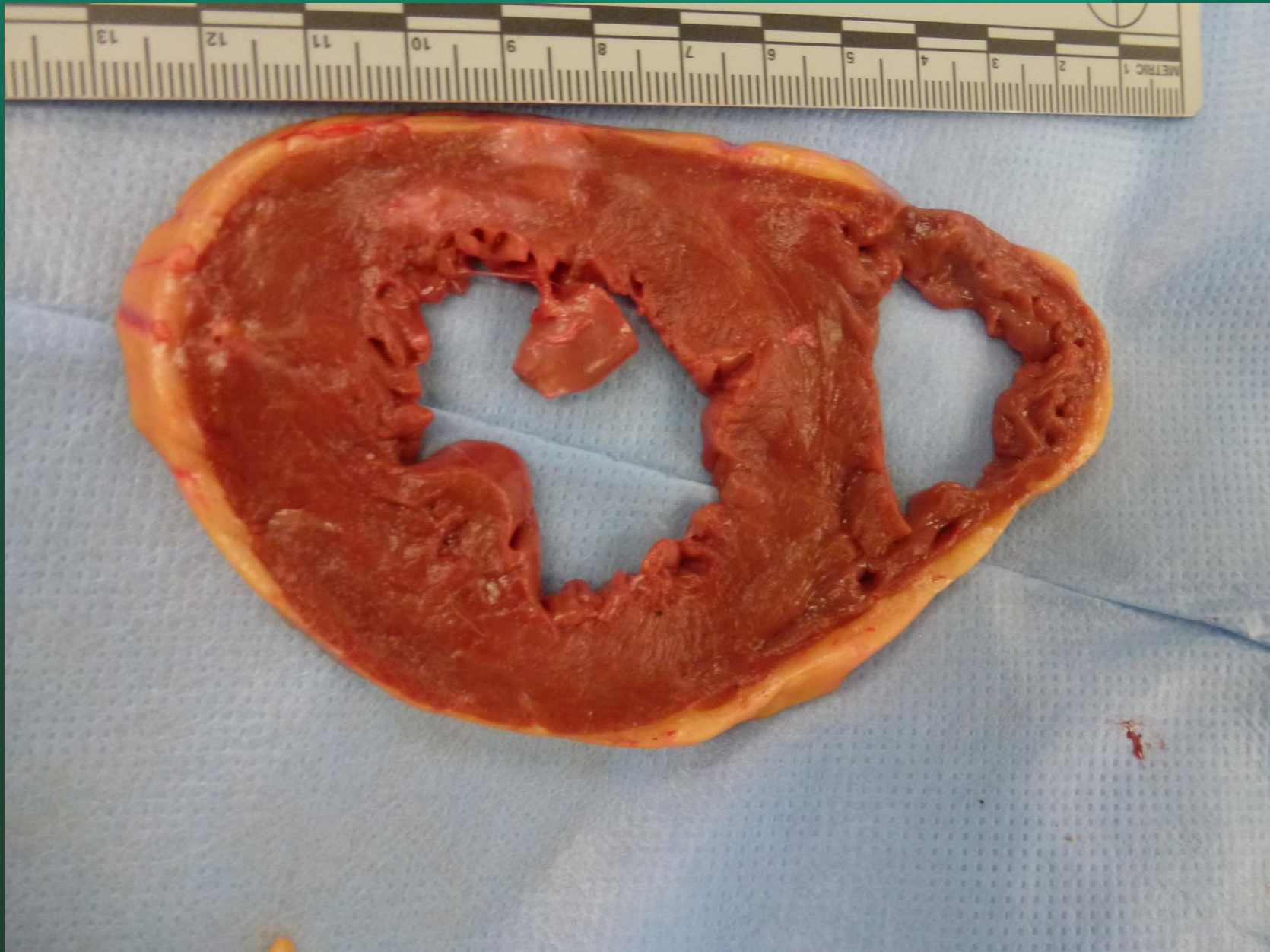
A STRANGE EXAMPLE OF COGNITIVE BIAS IN A CASE OF ANOXIC ENCEPHALOPATHY

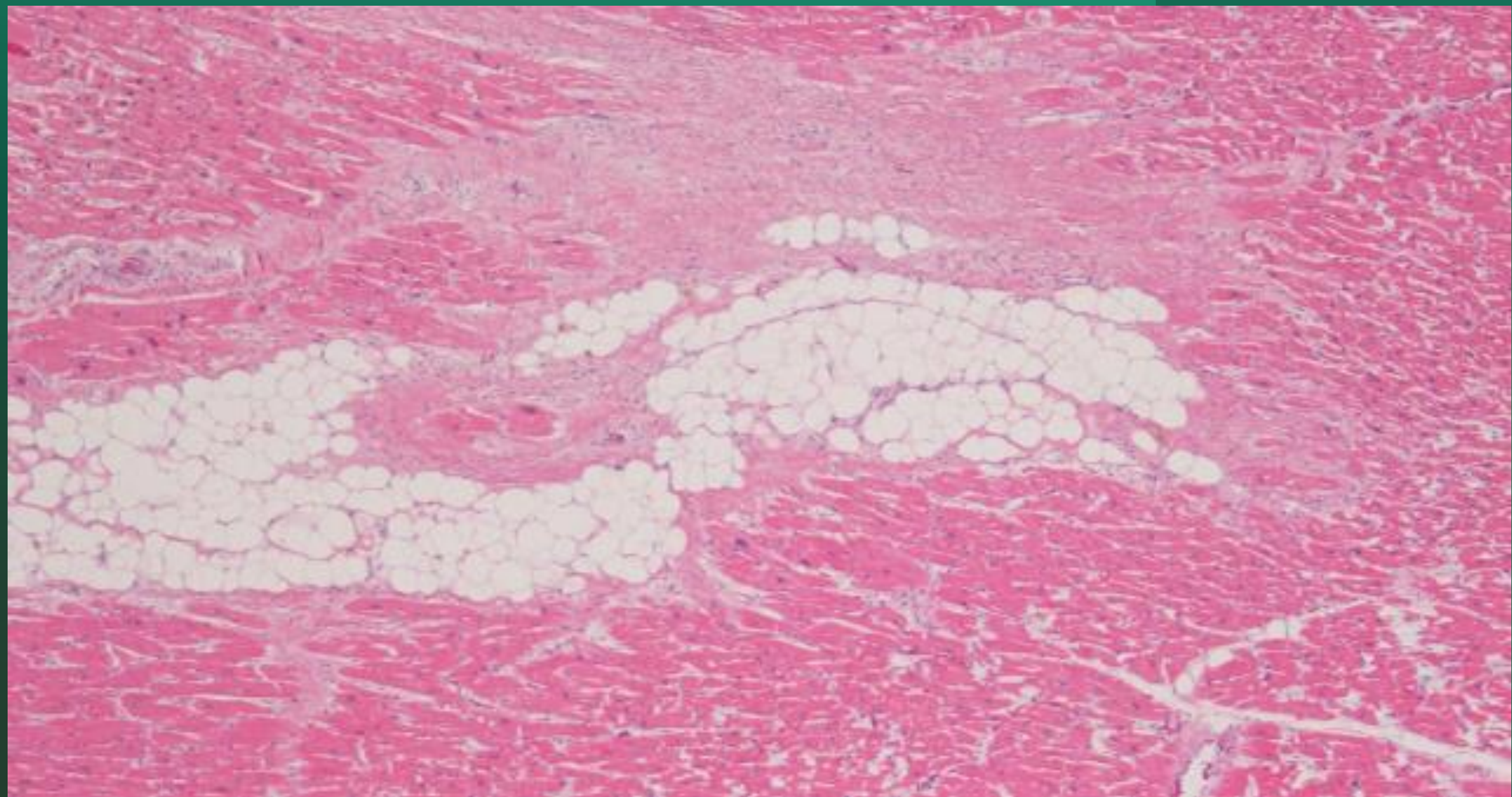
L. J. Dragovic, MD, FCAP, FAAFS, FNAME

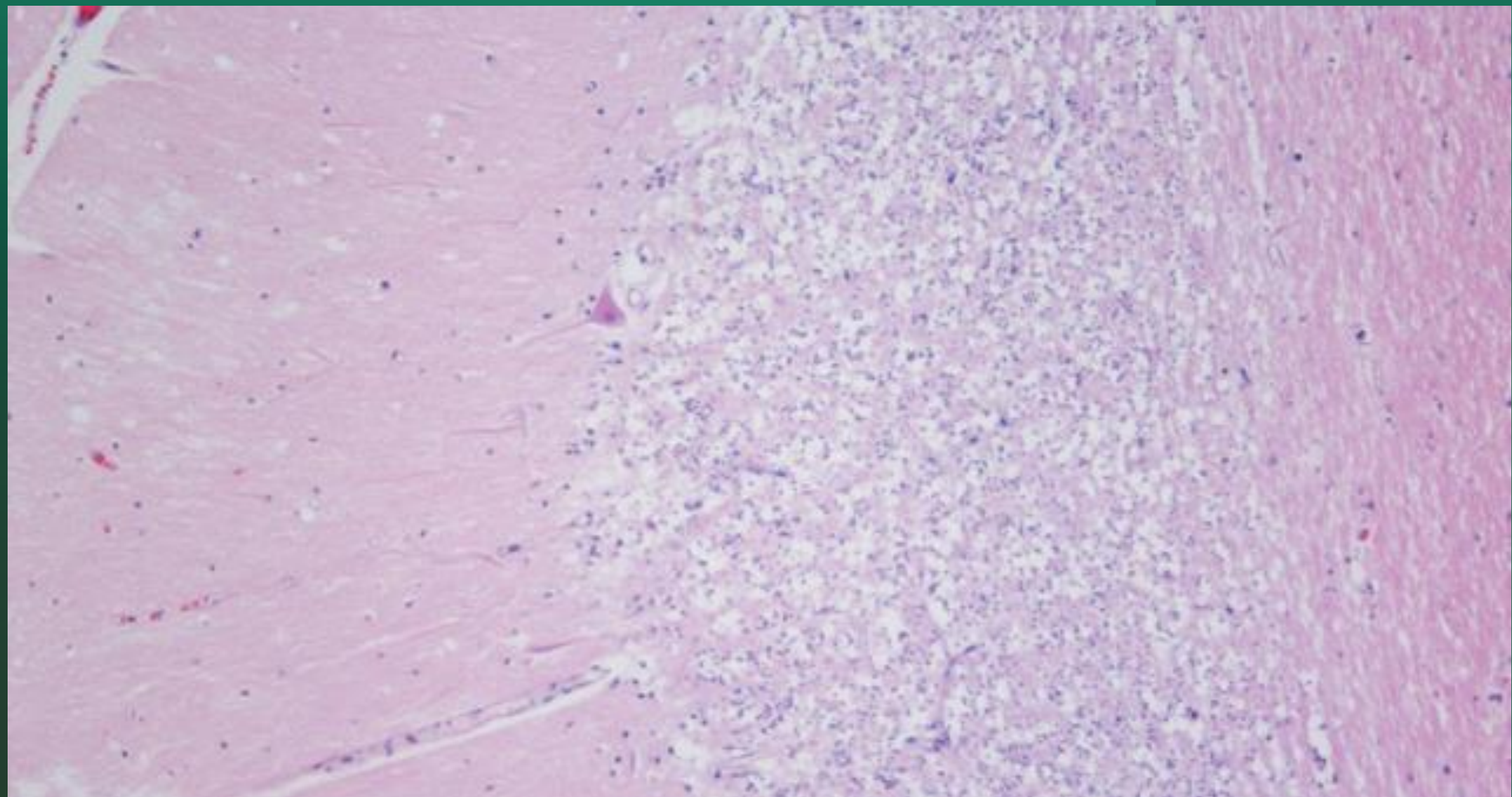
54 year old white male pronounced brain dead after one day of hospital stay:

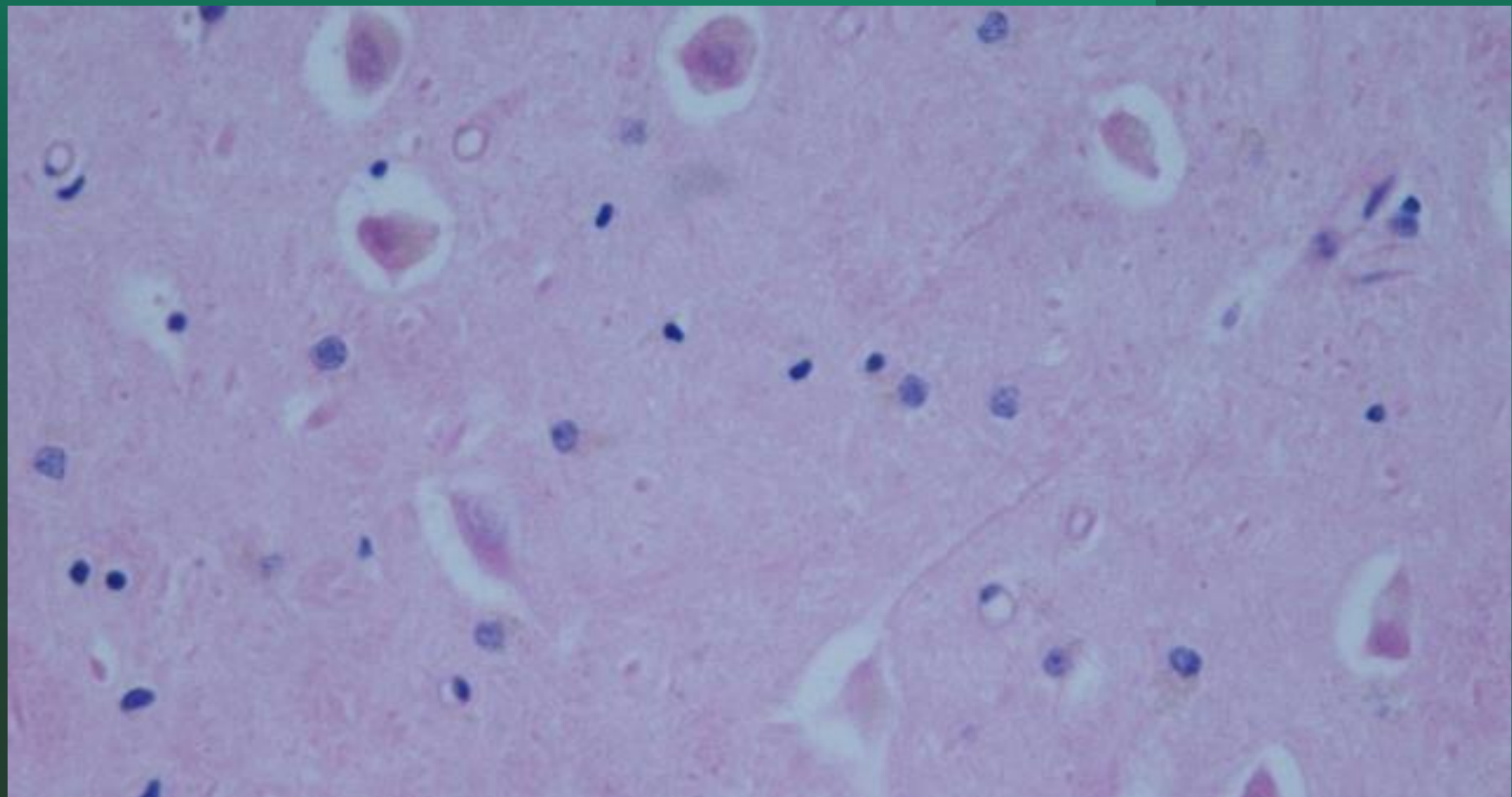
- CERTIFICATE OF DEATH: Anoxic Brain Injury
Acute Respiratory Failure
Cardiac Arrest
- MANNER OF DEATH: NATURAL

The forensic pathologist was told by the lead detective that the man had been found unresponsive in his jail cell.









Approximately one year later the following video footage became available as a result of a lawsuit:

